

# Automated localisation of optic disc in retinal colour fundus image for assisting in the diagnosis of glaucoma

Latifah Listyalina, Hanung Adi Nugroho\*, Sunu Wibirama, Widhia KZ Oktoeberza

Department of Electrical Engineering and Information Technology,  
Faculty of Engineering, Universitas Gadjah Mada,  
Jalan Grafika 2, Kampus UGM, Yogyakarta 55281, Indonesia

## Article history:

Received: 27 March 2017 / Received in revised form: 10 May 2017 / Accepted: 27 May 2017

## Abstract

Optic disc (OD), especially its diameter together with optic cup diameter can be used as a feature to diagnose glaucoma. This study contains two main steps for optic disc localisation, i.e. OD centre point detection and OD diameter determination. Centre point of OD is obtained by finding brightness pixel value based on average filtering. After that, OD diameter is measured from the detected optic disc boundary. The proposed scheme is validated on 30 healthy and glaucoma retinal fundus images from HRF database. The results are compared to the ground truth images. The proposed scheme obtains evaluation result ( $E$ ) for healthy and glaucoma images is 0.23 and 0.21, respectively. Evaluation result ( $E$ ) shows the ratio between the average distance of OD centre point obtained by proposed method and that of the ground truth divided by average difference between OD diameter by proposed method and that of the ground truth. The lesser the value of  $E$  the better the performance of the method in detecting OD centre point and determining the OD diameter. Therefore, these results indicate successful implementation of automated OD localisation by detecting OD centre point and determining OD diameter in healthy and glaucoma images. Moreover, this scheme has a potential to be implemented in the development of a computerised glaucoma diagnosis system.

**Keywords:** Optic disc centre point; optic disc diameter; retinal image; glaucoma.

## 1. Introduction

There are some retinal related diseases and common causes of early visual loss and blindness such as diabetic retinopathy, age-related macular degeneration (ARMD) and glaucoma. More than 60 million glaucoma cases in the world, and by 2020 the cases predicted to increase to be 80 million, particularly for adults with more than 40 years of age. Glaucoma is the second leading cause of blindness after refractive and cataract errors [1]. This disease is a neuro-degenerative eye condition that is irreversible. However, many patients become aware of the disease in the last stages of glaucoma due to lack of effective early screening systems [2,3].

Fundus images are useful to document the condition of optic disc (OD), optic nerve, vitreous, fovea, macula, retina and eye's blood vessels [4]. Probability and specific criteria of glaucoma progression can be diagnosed by measuring cup to disc ratio (CDR), since the enlargement in the cupping of optic nerve head (ONH) corresponds to the increased ganglion cell death. CDR is defined as the ratio of the vertical height of the optic cup to the vertical height of the optic disc. In glaucoma, the nerve fibres loss at superior and inferior poles may cause a vertical enlargement of the cup. Fig. 1 shows the

example of retinal optic disc for healthy and glaucoma patient. High risk or severe stage of glaucoma is determined by the ratio value of optic cup to optic disc is greater than 0.65 [5, 6].

Optic disc is one of the major parts of a retinal fundus image; appears as a very bright region compared to its surrounding. In a circular area of optic disc, there are blood vessels and optic nerves enter to the retina of human eyes. An accurate identification of the optic disc boundary and changes in optic disc shape and area may be can be used to indicate the some diseases progression, especially glaucoma [7-10].

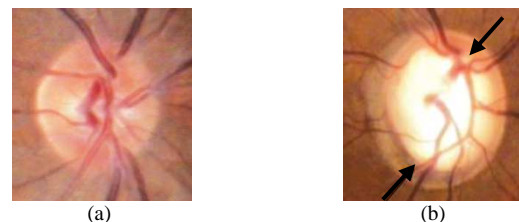


Fig. 1. Example of (a) Healthy OD and (b) Glaucoma OD [11]

Several glaucoma feature detection including optic disc and cup segmentation, and also glaucoma detection itself have been developed. Zhang *et al.* [5] developed an approach to localise region of interest (RoI) of optic disc for glaucoma detection by removing fringe of fundus images as noise that obtained from external lighting. Kaur *et al.* [12] described

\* Corresponding author. Tel.: +62-274-552305; fax: +62-274-552305.  
Email: adinugroho@ugm.ac.id.

optic disc boundary detection techniques. In this study, blood vessels were eliminated with morphological closing technique. After eliminating the vessels, optic disc boundary was segmented. This result can be obtained using active contour model (ACM) after 150 iterations. Optic disc boundary manually hand labelled by an expert was used as ground truth.

Optic disc and optic cup segmentations based on double thresholding have been employed [1]. The radius of cup to disk ratio is measured by applying circular Hough transform. The proposed method is validated on HRF dataset then the result is compared to medical expert diagnosis. While [2, 8] segment optic disc and optic cup based on morphological operation.

Automated localisation of retinal optic disc using Hough transform was also proposed by [13]. Green channel was selected in this research because it had a good contrast between optic disc and others. In retinal fundus images, opening and closing transformations were suitable for shapes identifying. Then, background removal and filtering of blood vessel was performed. To increase homogeneity of background, shade corrected method was employed on each images. Then, binary image was computed by the thresholding method to trace the optic disc as brighter area than others. Finally, initial boundary was found as a circular centred from RoI which the Hough transformation was applied to detect the area of optic disc.

Many available optic disc detection and localisation methods are now commonly non-automatic and only work well in healthy retinal images. The proposed methods are addressed to overcome the problem of automated detection and localisation of optic disc in healthy and unhealthy (glaucoma) retinal colour images to assist ophthalmologists in diagnosing of glaucoma disease.

## 2. Materials and Methods

### 2.1. Database

In performing detection of optic disc, especially in diameter of optic disc, high resolution fundus (HRF) database was used [14]. A total of 30 retinal images consisting of 15 images of healthy patients and 15 images of glaucoma patients were collected from this database. The images were captured using Canon CR-1 fundus camera from 45° field of view (FoV) with different acquisition setting. HRF database has expert information such as diameter of optic disc and class condition of the eye whether healthy or glaucoma. From this proposed method, the diameter of optic disc can be used to facilitate the automatic detection of glaucoma in healthy and glaucoma retinal colour images.

### 2.2. Optic Disc Centre Point Candidate Detection

The first step of this method is to detect the optic disc centre point candidates. All steps conducted to detect the optic disc centre point in this research work are depicted in Fig. 2.

The retinal fundus image in HRF database consists of three components, namely the red, green and blue (RGB) channels.

The RGB colour space is one of the most used colour spaces, particularly for 8 bit digital images [14,15]. Red channel is the brightest image, the green channel has the best contrast and the blue channel image has the worse brightness and contrast. Thus, green channel is extracted. Then, optic disc is localised using circular average filter. This filter is implemented by creating circular average mask which has 51 of radius. After that, some bright pixel as a maximal pixel value are determined and then their centre point is obtained to produce the optic disc centre point candidate. By measuring the median coordinate value of row and column of all of the maximal pixels value. Detected centre point of optic is validated by measuring Euclidean distance to the centre point of ground truth image.

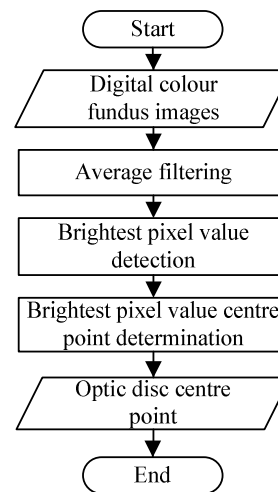


Fig. 2. Research flow of optic disc point candidate method

### 2.3. Automated Optic Disc Diameter Determination

All steps conducted to determine optic disc diameter depicted in Fig. 3. Initially, the optic disc centre candidate as the input in both optic disc and centre of macula detection should be determined. Green channel image which has the best contrast among other channels is chosen to be the processed image. As stated before that the optic disc appears as the bright region in retinal image, so that this property can be used to detect the centre of optic disc. In order to separate retinal image into several regions, i.e. bright and dark, the use of average filter is beneficial due to its ability to localise certain neighbourhood having similar intensity value. In this part,  $51 \times 51$  sized of filter window is used to apply average filter. This big filter size window is used to avoid bright lesion such as exudate appears as optic disc candidate. Afterwards, optic disc centre point is determined by finding the centre coordinate of bright region.

Having obtained the centre point of optic disc, the optic disc diameter determination method is started by developing the region of interest (RoI). The RoI has  $500 \times 500$  of size, smaller than the original image but large enough to cover the optic disc area. In order to extract the optic disc area, retinal blood vessels should be removed. At first, blood vessels are detected by using multiple bottom hat transformation with line structure element in 35 of size. The structure element is

rotated in twelve orientations with incremental angle of 15°.

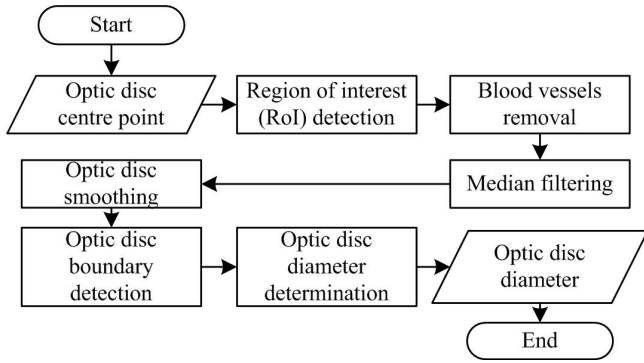


Fig. 3. Research flow of the automated optic disc diameter detection method

In the next step, blood vessel is eliminated. This process is done by adding the RoI image to the result of multiple bottom hat transformation images. Moreover, median filter is applied followed by the morphological closing operation and average filtering to get the smooth image of optic disc. Edge detection based on Sobel operator is then used to obtain the edge or the optic disc boundary. Then, length filter is implemented to eliminate the object which has the neighbourhood value lower than the threshold level  $T$ . Finally, by measuring the mean of the distance between most left and right boundary and between the most top and bottom boundary, optic disc diameter can be obtained. The obtained diameter together with optic cup diameter can be used in glaucoma diagnosis.

#### 2.4. Evaluation of The Proposed Scheme

This study is validated on 15 healthy and 15 glaucoma retinal images to detect OD centre point and determine OD diameter. To evaluate the performance of proposed scheme, the average Euclidean distance of centre of OD of the whole images is divided to the average OD diameter of the whole images as defined in (1).

$$E = \frac{\text{average of Euclidean distance}}{\text{average of diameter}} \quad (1)$$

### 3. Results and Discussion

#### 3.1. Optic Disc Centre Point Candidate

The description of the used of optic disc centre point candidate is focused on its application as a feature of glaucoma diseases. The example of HRF original colour image consists of red, green and blue channels. The proposed method is started by choosing the green channel due to having the highest contrast compared to the others as shown in Fig. 4 (a). Filtering is applied in the next step.

Average filtering providing blurred effect in image is worked in  $51 \times 51$  of size of window. Then, the next step is done by extracting the pixel coordinate having brightest or highest intensity value. Finally, the optic disc centre point candidate is achieved by determining the centre of the extracted pixel coordinate in the previous step. An example of detected optic disc centre point can be seen in Fig. 4 (b)

below which is marked with the blue marker.

Detected centre point of proposed method is then validated by measuring the average Euclidean distance to the ground truth as presented in Table 1 and Table 2. As shown in Table 1 and Table 2, the average Euclidean distance of detected centre point between proposed method and ground truth for healthy and glaucoma images are 74.03 and 73.31, respectively. These results denote that the proposed method is reliable for automatically detecting and localising optic disc in healthy and unhealthy (glaucoma) images proven by the similarity result of the average Euclidean distance from both of them.

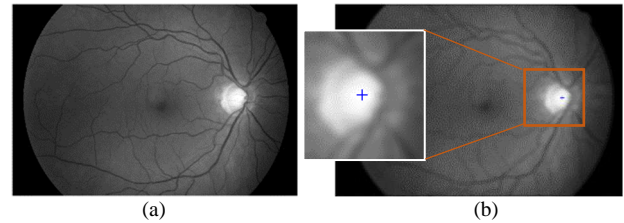


Fig. 4. (a) Green channel extraction (b) Optic disc centre point candidate

Table 1. The result of detected centre point of proposed method and ground truth (healthy)

Image	Proposed method (coordinate)		Ground truth (coordinate)		Euclidean distance (pixels)
	$x_1$	$y_1$	$x_2$	$y_2$	
01_h	2620	1136	2648	1155	34.25
02_h	904	1103	988	1085	85.91
03_h	2601	1156	2703	1153	102.04
04_h	1030	1086	966	1122	73.43
05_h	2660	1077	2684	1074	24.63
06_h	987	1179	933	1116	82.98
07_h	2777	1139	2798	1159	29.00
08_h	1029	1148	880	1055	175.64
09_h	2802	1056	2812	1076	22.36
10_h	914	1115	883	1128	33.62
11_h	2911	1124	2909	1124	2.00
12_h	1118	1089	997	986	158.90
13_h	2678	1099	2708	1098	30.02
14_h	1115	1186	918	1078	224.66
15_h	2684	1144	2701	1118	31.06
<b>Average</b>					<b>74.03</b>

#### 3.2. Automated Optic Disc Diameter Determination

The method for automated optic disc diameter detection consists of region of interest development, blood vessels removal, optic disc smoothing, optic disc boundary detection and optic disc diameter determination.

##### 3.2.1. Region of Interest (RoI) Development and Blood Vessels Removal

Based on optic disc centre point candidate, region of interest (RoI) is developed. Each of original images having resolution of  $3304 \times 2236$  is cropped into resolution of  $500 \times 500$  or  $250$  pixels left, right, up and down measured from

optic disc centre point candidate which serves as the reference point. RoI is conducted to fit the optic disc area in [8]. Fig. 5 shows the region of interest in this proposed method which only consists of optic disc and slightly blood vessels.

Table 2. The result of detected centre point of proposed method and ground truth (glaucoma)

Image	Proposed method (coordinate)		Ground truth (coordinate)		Euclidean distance (pixels)
	$x_1$	$y_1$	$x_2$	$y_2$	
01_g	2679	1077	2715	1070	36.67
02_g	1015	1082	873	1107	144.18
03_g	2637	1119	2647	1176	57.87
04_g	1056	1145	990	1094	83.41
05_g	2716	1083	2748	1074	33.24
06_g	972	1135	941	1159	39.21
07_g	2695	997	2746	1048	72.48
08_g	899	1036	934	1178	146.25
09_g	994	1092	930	1115	68.01
10_g	2606	1150	2633	1171	34.21
11_g	2595	1050	2644	1072	53.71
12_g	1004	967	1033	1065	102.20
13_g	2720	1123	2709	1141	21.10
14_g	950	1052	958	1129	77.41
15_g	2567	1124	2649	1145	84.65
<b>Average</b>					<b>73.31</b>

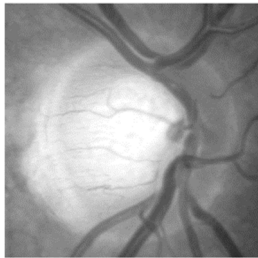

Fig. 5. Optic disc region of interest

As shown in Fig. 5, there are slightly blood vessels appear in RoI image. To extract optic disc area, retinal blood vessels must be removed. Early, blood vessels are detected using multiple bottom-hat transformation with line structure element in 35 of size. The structure element is rotated in twelve orientations with incremental angle of  $15^\circ$ . In this step only blood vessels and background appear in RoI image as shown in Fig. 6 (a). Having obtained the retinal blood vessels, blood vessels removal is applied by adding the RoI image to the result of multiple bottom-hat transformation image to produce blood vessels-free image as shown in Fig. 6 (b).

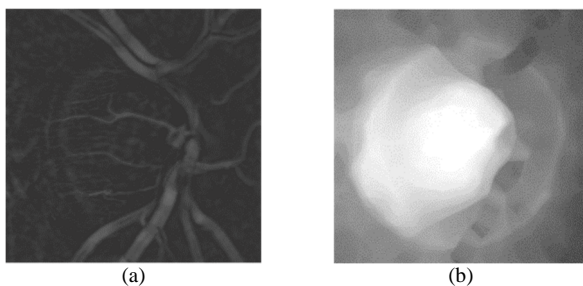


Fig. 6. (a) Detected blood vessels (b) Result of blood vessels removal

### 3.2.2. Optic Disc Smoothing

Optic disc smoothing is necessary in order to remove the rest of noise in RoI image. Vessels elimination leaves the vessels holes. These can be filled up using median filter and closing operation. Median filtering fills the holes with the pixel value of their neighbours. Median filter is applied by creating  $3 \times 3$  window and convolved on each image. After that, closing operation with disc structure element in 3 of radius is worked that successfully fills up the holes leaved by median filter. Finally, optic disc smoothing is done by applying average filter. Average filter sets the pixel value both in the background and optic disc area uniformly. Fig. 7 shows the examples results of median filtering and closing operation result.

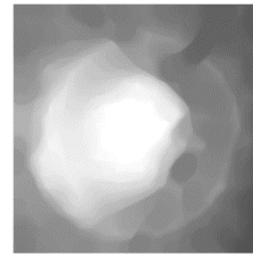


Fig. 7. The result of optic disc smoothing

### 3.2.3. Edge Detection

Edge detection works by computing an approximation of the gradient of the image intensity function. This method is used to extract the optic disc boundary as shown in Fig. 8 (a). Having obtained the result of edge detection, length filter is applied. Length filter works by eliminating the object which has the neighbourhood value lower than threshold level  $T$ . This method is aimed to reduce the noise pixels that exists on the result of Sobel detection. The new produced image can be seen in Fig. 8 (b).

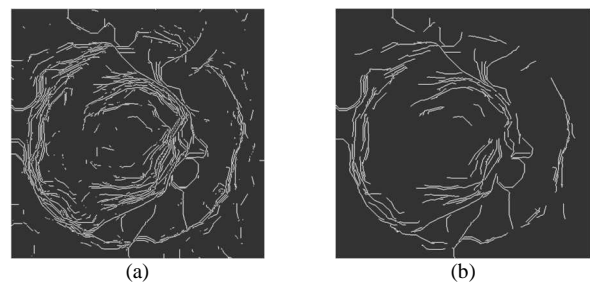


Fig. 8. (a) Detected optic disc boundary (b) Result of length filter

### 3.2.4. Optic Disc Diameter Determination

Optic disc diameter determination becomes the last step in this method that aims to get the optic disc diameter automatically. Some points must be detected in the farthest up and down distance from optic disc point candidate coordinate. Then, two coordinates are achieved which serve as up and down optic disc boundary and become the reference points of diameter measurement together with optic disc point candidate. Optic disc diameter is obtained by firstly

connecting those two points. The distance of those points is then associated as optic disc diameter.

As mentioned before, HRF dataset is accompanied with the optic disc diameter as the ground truth on every image along with the diagnosis. Those diameters are plotted on a retinal image to specify whether vertical or horizontal diameter provided by the ground truth. As shown in Fig. 9, these are the results of plotted vertical and horizontal diameter of ground truth in healthy and glaucoma classes.

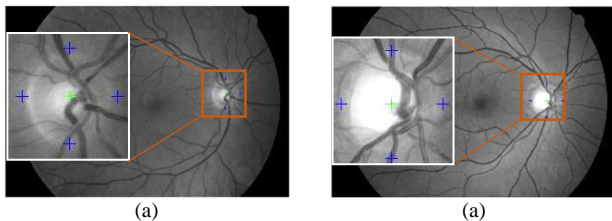


Fig. 9. Vertical and horizontal optic disc diameter of ground truth images; (a) healthy and (b) glaucoma

From that figure, it is proven that the provided diameter refers to vertical diameter of optic disc since the provided diameter more precisely represents the vertical diameter of optic disc than horizontal diameter. However, on this proposed method, both vertical and horizontal diameter are measured but only vertical diameter is validated with the ground truth. Fig. 10 (a) shows example of images in which vertical and horizontal optic disc diameter successfully obtained by proposed method, while Fig. 10 (b) shows example of images in which vertical and horizontal optic disc diameter unsuccessfully obtained by proposed method.

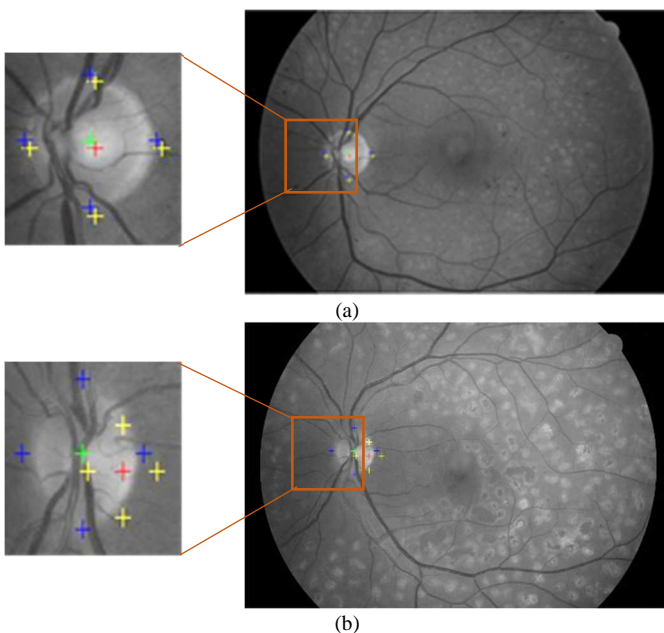


Fig. 10. (a) Successful detected vertical and horizontal optic disc diameter in retinal image; (b) Unsuccessful detected vertical and horizontal optic disc diameter in retinal image

In order to validate our algorithm, the results of the proposed scheme are compared to the ground truth. Table 3 and Table 4 represent the comparison of optic disc vertical diameter of each image by using the proposed method and

ophthalmologist's measurement.

As shown in Table 3 and Table 4, the error values indicating the difference of diameter between the ground truth and the proposed scheme are relatively small; 21.82% for healthy and 15.25% for glaucoma patients. However, one significant error still occurs due to the presence of blood vessels in the optic disc which may lead to false detection of optic disc boundary.

Table 3. The result of vertical diameter proposed method and ground truth (healthy)

Image	Proposed method diameter (pixels)	Ground truth diameter (pixels)	Error (pixels)	Error (%)
01_h	394	402	8	1.99
02_h	364	416	52	12.5
03_h	233	424	191	45.05
04_h	287	414	127	30.68
05_h	384	426	42	9.86
06_h	319	373	54	14.48
07_h	289	408	119	29.17
08_h	454	398	56	14.07
09_h	165	400	235	58.75
10_h	332	384	52	13.54
11_h	354	385	31	8.05
12_h	356	374	18	4.81
13_h	244	360	116	32.22
14_h	227	352	125	35.51
15_h	413	354	59	16.67
<b>Average</b>	<b>321</b>	<b>391.33</b>	<b>85.66</b>	<b>21.82</b>

Table 4. The result of vertical diameter proposed method and ground truth (glaucoma)

Image	Proposed method diameter (pixels)	Ground truth diameter (pixels)	Error (pixels)	Error (%)
01_g	352	365	13	3.56
02_g	382	372	10	2.69
03_g	332	430	98	22.79
04_g	422	393	29	7.38
05_g	182	374	192	51.34
06_g	268	391	123	31.46
07_g	405	385	20	5.19
08_g	398	384	14	3.65
09_g	267	358	91	25.42
10_g	276	368	92	25.00
11_g	383	408	25	6.13
12_g	368	379	11	2.90
13_g	398	335	63	18.81
14_g	398	331	67	20.24
15_g	393	402	9	2.24
<b>Average</b>	<b>348.27</b>	<b>378.33</b>	<b>57.13</b>	<b>15.25</b>

### 3.3. Evaluation of The Proposed Scheme

The evaluation step is conducted to analyse obtained results and to know the performance of proposed scheme in detecting OD centre point and determine OD diameter. In this study, evaluation ( $E$ ) is measured by dividing between average Euclidean distance of OD centre point and average of OD diameter as formulated in (1). For 15 healthy images, the

evaluation ( $E$ ) obtained is 0.23, while for 15 glaucoma images it obtains 0.21. These evaluation values indicate that proposed scheme is able to localise optic disc by detecting OD centre point and determining OD diameter in both of healthy and glaucoma images. Moreover, this scheme is reliable to be implemented in the development of automated glaucoma diagnosis system.

#### 4. Conclusion

A developed algorithm for optic disc localisation on healthy and unhealthy (glaucoma) colour fundus images to facilitate the diagnosis of glaucoma has been described. Based on the performance evaluation of two main steps conducted, obtained ( $E$ ) for healthy and glaucoma images is 0.23 and 0.21, respectively. These results indicate that the proposed scheme is able to detect OD centre point and determine OD diameter. The notable thing in this study is the exactness detection OD centre point since positioning RoI to determine OD diameter is based on the detected OD centre point. Moreover, some filtering techniques can be employed to extent the detection of OD centre point. However, further research should be made for improving the OD localisation performance on retinal fundus images to assist ophthalmologists in diagnosing glaucoma disease.

#### Acknowledgements

This research work is funded by Directorate General of Higher Education, Ministry of Research, Technology and Higher Education, Republic of Indonesia. The authors would like to acknowledge the contributions of dr. Muhammad Bayu Sasongko, Ph.D. from Department of Ophthalmology, Faculty of Medicine, Universitas Gadjah Mada which is also an ophthalmologist from Sardjito General Hospital, Yogyakarta for his meaningful sharing of knowledge.

#### References

1. M. K. Dutta, A. K. Mourya, A. Singh, M. Parthasarathi, R. Burget, and K. Riha, *Glaucoma detection by segmenting the super pixels from fundus colour retinal images*, in *International Conference on Medical Imaging, m-Health and Emerging Communication Systems (MedCom)*, 2014, pp. 86-90.
2. A. M. Jose and A. A. Balakrishnan, *A novel method for glaucoma detection using optic disc and cup segmentation in digital retinal fundus images*, in *International Conference on Circuit, Power and Computing Technologies (ICCPCT)*, 2015, pp. 1-5.
3. Y.-C. Tham, X. Li, T. Y. Wong, H. A. Quigley, T. Aung, and C.-Y. Cheng, *Global prevalence of glaucoma and projections of glaucoma burden through 2040: a systematic review and meta-analysis*, *Ophthalmology*. 121 (2014) 2081-2090.
4. Z. Zhang, B. H. Lee, J. Liu, D. W. K. Wong, N. M. Tan, J. H. Lim, et al., *Optic disc region of interest localization in fundus image for glaucoma detection in ARGALI*, in the *5th IEEE Conference on Industrial Electronics and Applications (ICIEA)*, 2010, pp. 1686-1689.
5. D. D. Patil, R. R. Manza, G. C. Bedke, and D. D. Rathod, *Development of primary glaucoma classification technique using optic cup & disc ratio*, in *International Conference on Pervasive Computing (ICPC)*, 2015, pp. 1-5.
6. D. D. Patil, R. Manza, and G. C. Bedke, *Diagnose glaucoma by proposed image processing methods*, *Int. J. Comp. Applicat.* 106 (2014) 14-17.
7. P. K. Kohli, *Exact detection of optic disc in retinal images using segmentation based on level set method and morphological operations*, Master Thesis, Computer Science and Applications, Thapar University, Patiala, 2012.
8. H. A. Nugroho, L. Listyalina, N. A. Setiawan, S. Wibirama, and D. A. Dharmawan, *Automated segmentation of optic disc area using mathematical morphology and active contour*, in *International Conference on Computer, Control, Informatics and its Applications (IC3INA)*, 2015, pp. 18-22.
9. M. Zubair, A. Yamin, and S. A. Khan, *Automated detection of optic disc for the analysis of retina using color fundus image*, in *IEEE international conference on Imaging systems and techniques (IST)*, 2013, pp. 239-242.
10. P. Choukikar, A. K. Patel, and R. S. Mishra, *Segmenting the optic disc in retinal images using bi-histogram equalization and thresholding the connected regions*, *Int. J. Emerg. Technol. Adv. Eng.* 4 (2014) 10.
11. S. Bhartiya, R. Gadia, H. S. Sethi, and A. Panda, *Clinical evaluation of optic nerve head in glaucoma*, *J. Curr. Glaucoma Prac.* 4 (2010) 115-132.
12. J. Kaur and D. H. Sinha, *Automated localisation of optic disc and macula from fundus images*, *Int. J. Adv. Res. Comp. Sci. Soft. Eng.* 2 (2012) 242-249.
13. S. Sekhar, W. Al-Nuaimy, and A. K. Nandi, *Automated localisation of retinal optic disk using Hough transform*, in *5th IEEE International Symposium on Biomedical Imaging (ISBI): From Nano to Macro*, 2008, pp. 1577-1580.
14. P. I. J. Odstrcilik, *Analysis of retinal image data to support glaucoma diagnosis*, Ph.D. Thesis, Department of Biomedical Engineering, Brno University of Technology, Czech Republic, 2014.
15. F. Zana and J.-C. Klein, *A multimodal registration algorithm of eye fundus images using vessels detection and Hough transform*, *IEEE Trans. Med. Imag.* 18 (1999) 419-428.